

Expression of MMP-2 as Biological Markers of Invasion Potential in Mucoepidermoid Carcinoma of the Oral and Maxillofacial Region (Immunohistochemical Study)

*Mustafa G. Taher (Assist. Lecturer ,M.Sc. Oral pathology)

**Bashar H. Abdullah (Assist. Professor)

***Luay E. Al-Khuri (Assist. Professor)

Abstract

Background: Mucoepidermoid carcinoma (MEC) is a malignant epithelial neoplasm characterized by the proliferation of epidermis, mucous, and intermediate cells in various proportions, it represents up to 10% of all major salivary glands tumors and 15% to 23% of minor glands. It exhibits varying degrees of differentiation and histologic grade as well as widely diverse biologic behavior. Its grading system is based on different histological components seen on hematoxylin and eosin slide which is still a controversial issue. This study evaluates the immunohistochemical expression of MMP-2 antibodies as markers of local invasion of MEC to be correlated with the tumor grade and stage.

Aim of the study: Immunohistochemical evaluation MMP-2 as a biological markers of local invasion in oral and maxillofacial salivary MEC in relation to grading and staging of MEC.

Materials and Methods: The study involved 22 salivary gland MEC tissue samples for the period from 1972 to 2010. Age, sex, site, stage and histologic grades were recognized. The samples were immunohistochemically stained with monoclonal antibodies to matrix metalloproteinase-2 (MMP-2).

Results: The sample comprised 14 males and 8 females in (1.75:1) ratio. The age range of the patients was between 19 and 65 years with a mean of (45.9±10.53). The stage of MEC had a significant relationship with Brandwein grading system (P=0.039). Concerning the site and sex distribution, neither site nor sex had a significant statistical relationship with Brandwein grading system (p> 0.05). The mean of matrixmetalloprotenase-2 expressed by MMP-2 immunomarker was (41.7±23.13) with no significant relation to tumor grade and stage . Regarding the predominant cells, no significant relations were found neither with the grade nor the stage of study samples.

Conclusions: In all samples, matrixmetalloproteinase-2 had a non significant relationship with tumor grade and stage. No correlation was found between the histological grading of MEC and its biological behavior concerning invasion potential.

Keywords: Salivary mucoepidermoid carcinoma, MMP-2.

*Department of Pathology / College of Medicine / Diyala University/ Diyala/ Iraq.

**Department of Pathology / College of Dentistry / Baghdad University/ Baghdad / Iraq.

***Department of Pathology / College of Medicine / Baghdad University/ Baghdad / Iraq.

الخلاصة

الخلفية: إن سرطان الغدد اللعابية الحرفشي المخاطي هو ورم طلائي خبيث يتميز بتكاثر الخلايا الحرفشية والمخاطية والمتوسطة النوع بنسب مختلفة، حيث تمثل ما يصل إلى ١٠٪ من مجموع أورام الغدد اللعابية الرئيسية و ١٥٪ إلى ٢٣٪ من الغدد الثانوية، حيث إنه يسلك درجات متفاوتة من درجة التمايز النسيجي وكذلك على نطاق السلوك البيولوجي. ويعتمد نظام التصنيف على المكونات النسيجية المختلفة حيث ينظر إليه من خلال صبغة الهيماتوكسيلين والايوسين التي لا تزال مسألة مثيرة للجدل.

تهدف الدراسة إلى تقييم الظهور الكيميائي النسيجي المناعي لـ (MMP-2) في سرطان الغدد اللعابية المخاطية الحرفشية لمنطقة الفم والوجه والفكين ومقارنتها مع نظام التصنيف والمراحل لمرض السرطان المخاطي الحرفشي.

الهدف من هذه الدراسة: التقييم الكيميائي المناعي لـ MMP-2 باعتبارها علامات بيولوجية لتقييم قابلية الاختراق في سرطان الغدد اللعابية المخاطية الحرفشية لمنطقة الفم والوجه والفكين ومقارنتها مع نظام التصنيف والمراحل لمرض.

المواد وطرق العمل: تضمنت الدراسة اثنان وعشرون عينة من السرطان المخاطي الحرفشي المحفوظة بمادة الفورمالين والمطمورة بشمع البارافين والتي جمعت من أرشيف المختبرات من عام ١٩٧٢ - ٢٠١٠. تم التأكد من العمر، الجنس، موقع الورم و نظام التصنيف والمراحل لمرض السرطان المخاطي الحرفشي من خلال تشخيص و فحص مقاطع الهيماتوكسيلين والايوسين. تم صبغ المقاطع بأجسام مناعية مضادة أحادية النسل موجهة إلى (MMP-2) لتقييم قابلية الاختراق وأجريت مقارنة لقيم المؤشرات المذكورة مع سرطان المخاطي الحرفشي.

النتائج: اشتملت الدراسة على ١٤ ذكر و ٨ إناث لتكون نسبة الذكور إلى الإناث (١:٧٥). كان معدل العمر للمرضى المصابين بمرض السرطان المخاطي الحرفشي بين ١٩ و ٦٥ سنة وبمعدل (٤٥.٩±١٠.٥٣). إن مرحلة السرطان له علاقة إحصائية مباشرة مع نظام التصنيف السرطان لـ (Brandwein) ($P \leq 0.05$).

بالنسبة للجنس والعمر وموقع السرطان، لا توجد علاقة إحصائية مع تصنيف السرطان لـ (Brandwein) ($P \leq 0.05$). إن معدل الانزيمات البروتينية الخارج خلوية والمعبرة من خلال الأجسام المناعية الموجهة إلى (MMP-2) كانت (٢٣,١٣±٤١,٧)؛ وعلى كل حال لم تصل إلى علاقة إحصائية مهمة مع تصنيف السرطان ومرحلة السرطان، أما بخصوص الخلايا السائدة، لا توجد علاقات مهمة لعينات الدراسة مع تصنيف السرطان ولا مع مرحلة السرطان.

الاستنتاجات: في جميع العينات، الانزيمات البروتينية الخارج خلوية والمعبرة من خلال الأجسام المناعية الموجهة إلى (MMP-2) كانت على علاقة غير هامة مع تصنيف السرطان ولا مع مرحلة السرطان. ولم يتم العثور على الارتباط بين الدرجة النسيجية للسرطان و السلوك الحيوي من حيث قابلية الاختراق.

مفاتيح الكلمات: سرطان الغدد اللعابية الحرفشي المخاطي، الانزيمات البروتينية الخارج خلوية (MMP-2)

Introduction

Salivary gland tumors (SGTs) constitute an important area in the field of oral and maxillofacial pathology, its incidence around the world ranges from about 1.0 to 6.5 cases per 100,000 people, it represents 2-4% of head and neck neoplasms [1].

Mucoepidermoid carcinoma (MEC) is the most common malignant salivary gland tumors, with uniform age distribution between the ages of 20 and 70 years [1,2], also it is the most common malignant Salivary gland tumors in children [3]. It makes up 10% of all major gland tumors and 15% to 23% of minor gland tumors. MEC is most common in the parotid gland and usually appears as an asymptomatic swelling. Pain or facial nerve palsy may develop,

usually in association with high-grade tumors. The minor glands constitute the second most common site [1, 4].

Histopathologically MEC is composed of a mixture of mucus-producing cells, intermediate and squamous (epidermoid) cells. MEC have been categorized into one of three histopathologic grades based on amount of cyst formation, degree of cytologic atypia and relative numbers of mucous, epidermoid, and intermediate cells [1].

Many investigators have tried to define histologic features that have prognostic significance and proposed various grading schemes [5, 6]. In the literature, the histopathologic grading criteria of MEC remain controversial and based on several histological components (Intra cystic

component, necrosis, mitoses, pattern of tumor invasion, anaplasia and bony invasion).

Matrixmetalloproteinase-2 (MMP-2) plays an important role in the remodeling of the extracellular matrix in both physiologic and pathologic states and thus plays an important role in tumor progression, cancer invasion and metastasis. MMP-2 have the ability for degradation of proteins in the extracellular matrix, it proteolytically digests gelatin (denatured collagen). It is also involved in the invasion and metastasis of MEC. The MMP-2 marker is useful in determining the invasion ability of MEC [7].

In an attempt to define the possible biological behavior underlying the discrepancy of MEC, immunohistochemical expression of matrixmetalloproteinase-2 as a marker for local invasion potential has been measured to be correlated with MEC grade and stage.

Materials and Methods

Twenty two formalin-fixed paraffin-embedded tissue blocks of MEC of the salivary gland were collected from the Department of Oral Diagnosis / College of Dentistry / Baghdad University for the period from 1972 to 2010. Four-micrometer-thick sections were cut from each paraffin tissue block and stained with hematoxylin and eosin for diagnostic confirmation and histological grading. Tumors were classified into low, intermediate and high grade MEC according to Brandwein grading system [8]. TNM stage was applied to 18 cases only in which the required clinical data relevant to tumor stage were properly mentioned in the case sheet. Another 4- μ m section was cut from each tissue block and mounted on positively charged slides (Esco, USA) to be stained with monoclonal antibodies to MMP2 (USBiological-M2420-52A). Negative and positive tissue controls were included into each immunohistochemical run.

Immunohistochemical staining procedure

Slides were baked in hot air oven at 65°C overnight. Sections were sequentially dewaxed through a series of xylene, graded alcohol and water immersion steps. For MMP2; Endogenous peroxidase activity was blocked with 0.03 % hydrogen peroxide followed by blocking the nonspecific antibody binding with normal goat serum (USBiological-I7506A).; All slides was followed by the application of the primary antibodies with a dilution of 1:40 for MMP2. The slides were incubated for 1 h at 37°C and then kept at 4°C in a humid chamber overnight. Next day, after washing with PBS, biotinylated antimouse IgG were applied to the sections, incubated and rinsed with a stream of PBS. Conjugated antibodies were visualized with DAB chromogen. Sections were counterstained with Mayer's hematoxylin for 1–2 min, dehydrated and mounted.

Assessment of immunohistochemical results Assessment of MMP-2

All MEC slides were scanned at low power (X10) to select 5 fields showing the highest positive staining for MMP-2 marker in tumor stromal tissues. Staining for MMP-2 was measured semiquantitatively as the percentage of positively stained cell membrane, and assigned to four categories, so the degree of staining was scored as follows: 0, none; 1, less than 10%; 2, 10% to 50%; and 3, more than 50%. The average percent of the five fields was calculated (10).

Results

The sample comprised 14 males and 8 females with a male / female ratio (1.75:1). The age range of the patients with mucoepidermoid carcinoma was between 19 and 65 years with a mean of (45.9 \pm 10.53). The Submandibular gland was the most predominantly affected (7cases) followed by palate (6 cases), then parotid gland (5 cases) and the lowest with buccal mucosa (4 cases).

According to Brandwein grading system, 7 cases were found as low grade, 8 were intermediate and 7 cases were high grade. Concerning the site and sex distribution, neither site nor sex had a significant statistical relationship with Brandwein grading systems ($p > 0.05$). TNM staging system of MEC (only 18 cases) showed, 7 cases being stage I, 3 cases stage II, 4 cases stage III and 4 cases stage IV. Data showed that the stage of MEC had a significant relationship with Brandwein grading system ($P=0.039$). The mean percent of matrix metalloproteinase-2 expressed by MMP-2 immunomarker was $(41.7 \pm 23.13)\%$ (Fig. 1); however no significant relationship was found neither with tumor grade nor with the stage. (Table 1)

Regarding the predominant cells (table 2) no significant relations was found neither with the grade nor the stage of study samples.

Discussion

MEC grading system depends on different histological components. Many investigators have tried to define histologic features that have prognostic significance and proposed various grading schemes [9,10,11,12];

Clinical aspects

According to sex distribution of MEC, males formed $14(63.63\%)$ while the females were $8(36.36\%)$ of the samples in a male / female ratio (1.75:1). This finding disagreed with some studies (28, 29, 30) which stated that females were more predominant; no statistically significant relations were found with Brandwein grading system. Regarding the TNM stage, staging was applied to 18 cases only in which the required clinical data relevant to tumor stage were properly recorded in the case sheet. A highly statistical significant relation was seen with Brandwein grading system ($P=0.039$), since Brandwein grading system contained a histological parameters which are relevant to tumor stage.

As mentioned, MEC consisted of three types of tumor cells, squamous, intermediate and mucous cell. The higher the squamous cells the higher the grade [4], in the present study only one case showed a squamous cells predominance which was a high grade and high tumor stage, however cell types had showed no significant statistical relation neither with grading systems nor with TNM stage. Such finding may be due to that the majority of cases were of low and intermediate grades.

Immunohistochemical findings

Assessment of MMP-2

The expression of matrix metalloproteinase was evaluated using MMP-2 antibody, as it is secreted by numerous cultured malignant cell lines, the originally speculated that it is the key enzyme in cancer growth and metastasis [13], no statistical significant has been seen in relation with tumor stage. This denotes that all grades of MECs have potent ability as other aggressive tumors to produce matrix metalloproteinase to dissolve extracellular matrix that facilitate direct invasion [7]. Several studies revealed that MMPs were involved in the invasion and metastasis of tumors. A study [13] showed that, the MMP-2 was the key enzyme in cancer growth and metastasis and other [14] revealed that Oral carcinomas patients with elevated MMP-2 activity had shorter disease free survival after treatment than patients with low gelatinase tumor activities, also previous study [15] explain the MMP-2 and their tissue inhibitors (TIMPs) in the morphogenesis of the normal salivary glands as well as in mechanisms of tumor invasion and metastasis.

In conclusion, no significant relations were found among the immunohistochemical findings obtained MMP-2 considering the invasion potential when correlated with the histological grading systems (or their components) obtained by the traditional

H&E staining. Although MEC is divided histologically into three grades, the biological behavior is still comparable in term of local invasion potential, hence histological grading is an inadequate way of assessment in the era of immunohistochemistry, genetics and

biological markers, since hematoxylin and eosin stained sections cannot predict truly the tumor behavior, an additional criteria should be studied, verified on longitudinal bases and added to the golden old standard criteria.

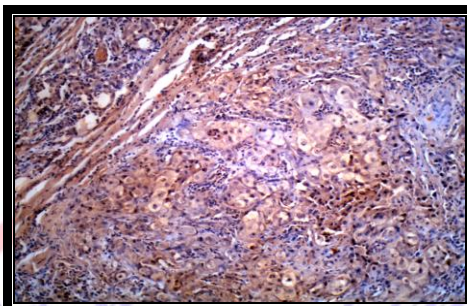


Figure (1): Photomicrograph showing positive MMP-2 immunostaining (High-grade MEC) (Original magnification X100).

Table (1): Immunohistochemical findings in relation to tumor grade and stage.

	Grade				Stage				
	Low N=7	Inter- mediate N=8	High N=7	P Value ANOVA	I N=7	II N=3	III N=4	IV N=4	P Value ANOVA
MMP-2% mean±sd	32.51±16.36	44.12±27.23	48.11±24.19	0.442 NS	42.57±26.11	39.53±9.79	43.00±28.21	41.95±23.90	0.998 NS

^{NS} Non-significant relation (p> 0.05)

Table (2): Predominant cells in relation with tumor grading and TNM stage.

		Predominant cells					Chi square Test
		Intermediate	squamous	mucous	mixed	Total	
Grading	Low	2 (28.6%)	0 (0.0%)	2 (28.6%)	3 (42.9%)	7 (100.0%)	0.139 ^{NS}
	Interme	5 (62.5%)	0 (0.0%)	3 (37.5%)	0 (0.0%)	8 (100.0%)	
	High	1 (14.3%)	1 (14.3%)	1 (14.3%)	4 (57.1%)	7 (100.0%)	
	Total	8 (36.4%)	1 (4.5%)	6 (27.3%)	7 (31.8%)	22 (100.0%)	
TNM Stage	I	4 (57.1%)	0 (0.0%)	2 (33.3%)	1 (25.0%)	7 (38.9%)	0.279 ^{NS}
	II	0 (0.0%)	0 (0.0%)	2 (33.3%)	1 (25.0%)	3 (16.7%)	
	III	2 (28.6%)	0 (0.0%)	2 (33.3%)	0 (0.0%)	4 (22.2%)	
	IV	1 (14.3%)	1 (100.0%)	0 (.0%)	2 (50.0%)	4 (22.2%)	
	Total	7 (100.0%)	1 (100.0%)	6 (100.0%)	4 (100.0%)	18 (100.0%)	

^{NS} Non-significant relation (p> 0.05)

References

- [1] Neville B.W., Damm D.D., Allen C.M., and Bouquot J.E.: Oral and maxillofacial pathology; Salivary gland pathology, Third Edition, Saunders (2009).
- [2] Elizabeth J. Rosen, MD, Salivary Gland Neoplasms, Grand Rounds Presentation, UTMB, Dept. of Otolaryngology, (2002); 26.
- [3] Carvalho AL, Nishimoto IN, Califano JA, et al. Trends in incidence and prognosis for head and neck cancer in the United States: a site-specific analysis of the SEER database. *Int J Cancer* 2005; 114(5):806–816.
- [4] Leon Barenes: *Surgical Pathology of the Head and Neck* 2009; 1,3rd.
- [5] Saw D, Lau WH, Ho JH, et al. Malignant lymphoepithelial lesion of the salivary gland. *Hum Pathol* 1986; 17(9): 914–923.
- [6] Laane CJ, Murr AH, Mhatre AN, et al. Role of Epstein-Barr virus and cytomegalovirus in the etiology of benign parotid tumors. *Head Neck* 2002; 24(5):443–450.
- [7] Kaori Kayano, Taketoshi Shimada, Takashi Shinomiya, Shigeru Nakai, Yasuo Hisa, Takanori Aoki, Motoharu Seiki, Yasunori Okada; Activation of pro-MMP-2 mediated by MT1-MMP in human salivary gland carcinomas: possible regulation of pro-MMP-2 activation by TIMP-2. *J. Pathol*, 202, 4, 403–411, 2004.
- [8] Brandwein MS, Ivanov K, Wallace D1 et al: Mucoepidermoid carcinoma: a clinicopathologic study of 80 patients with special reference to histological grading. *Am J Surg Pathol* 2001;25:835-845.
- [9] Browning L, Bailey D, Parker A. D2-40 is a sensitive and specific marker in differentiating primary adrenal cortical tumors from both metastatic clear cell renal cell carcinoma and pheochromocytoma. *J. Clin Pathol.*, 2008;61,293-296.
- [10] Takahiko Naka, MD, Carsten Boltze, MD, Doerthe Kuester, MD, Torss Oliver Schulz, MD, Amir Samii, MD, Christian Herold, MD, Helmut Ostertag, MD, and Albert Roessner, MD; Expression of Matrix Metalloproteinase (MMP)-1, MMP-2, MMP-9, Cathepsin B, and Urokinase Plasminogen Activator in Non-Skull Base Chordoma, *Am J Clin Pathol* 2004;122:926-930.
- [11] Stewart FW, Foote FW, Becker WF. Mucoepidermoid tumors of salivary glands. *Ann Surg* 1945; 122(5):820–844.
- [12] Auclair PL, Goode RK. Ellis GL Mucoepidermoid carcinoma of intraoral salivary glands: evaluation and application of grading criteria in 143 cases. *Cancer* 1992; 69:2021-2030.
- [13] Salo T, Liotta LA & Tryggvason K Purification and characterization of a murine basement membrane collagen-degrading enzyme secreted by metastatic tumor cells. *J Biol Chem* (1983); 258, 3058-3063.
- [14] Yorioka CW, Coletta RD, Alves F et al. Matrix metalloproteinase-2 and -9 activities correlate with the disease-free survival of oral squamous cell carcinoma patients. *Int. J. Oncol.* (2002); 20, 189–194.
- [15] H Nagel, R Laskawi, A Wahlers, B Hemmerlein: Expression of matrix metalloproteinases MMP-2, MMP-9 and their tissue inhibitors TIMP-1, -2, and -3 in benign and malignant tumours of the salivary gland 2004; 44, 3, 222–231.